

# Case Series of Pre-Operative Endovascular Embolization of Nasopharyngeal Angiofibroma Using Polyvinyl Alcohol Foam Particle: A Single Centre Experience

*by* Muhammad Yunus Amran

---

FILE	G_POLYVINYL_ALCOHOL_FOAM_PARTICLE_A_SINGLE_CENTRE_EXPERIENCE.PDF (484.94K)	WORD COUNT	4291
TIME SUBMITTED	06-FEB-2020 12:48PM (UTC+0700)	CHARACTER COUNT	25862
SUBMISSION ID	1252421803		

## Case Series of Pre-Operative Endovascular Embolization of Nasopharyngeal Angiofibroma Using Polyvinyl Alcohol Foam Particle: A Single Centre Experience

Muhammad Yunus Amran<sup>1, 2, 3\*</sup>, Ashari Bahar<sup>1, 2, 3</sup>

<sup>1</sup>Department of Neurology, Faculty of Medicine, Hasanuddin University, Makassar, South Sulawesi, Indonesia; <sup>2</sup>Brain Centre, Dr Wahidin Sudirohusodo General Hospital, Makassar, South Sulawesi, Indonesia; <sup>3</sup>Hasanuddin University Teaching Hospital, Hasanuddin University, Makassar, South Sulawesi, Indonesia

### Abstract

**Citation:** Amran MY, Bahar A. Case Series of Pre-Operative Endovascular Embolization of Nasopharyngeal Angiofibroma Using Polyvinyl Alcohol Foam Particle: A Single Centre Experience. Open Access Maced J Med Sci. <https://doi.org/10.3889/oamjms.2019.754>

**Keywords:** Nasopharyngeal angiofibroma; Embolization; Vascular tumour

**\*Correspondence:** Muhammad Yunus Amran, Department of Neurology, Medical Faculty of Hasanuddin University Brain Centre, Dr Wahidin Sudirohusodo General Hospital, Hasanuddin University Teaching Hospital, Makassar, South Sulawesi, Indonesia. Email: [yunusamran10@gmail.com](mailto:yunusamran10@gmail.com)

**Received:** 16-Jun-2019; **Revised:** 30-Jul-2019; **Accepted:** 01-Aug-2019; **Online first:** 12-Aug-2019

**Copyright:** © 2019 Muhammad Yunus Amran, Ashari Bahar. This is an open-access article distributed under the terms of the Creative Commons Attribution-NonCommercial 4.0 International License (CC BY-NC 4.0)

**Funding:** This research did not receive any financial support

**Competing interests:** The authors have declared that no competing interests exist

**BACKGROUND:** Nasopharyngeal Angiofibroma is a rare neoplasm in the sphenopalatine foramen. This tumour is histologically benign, but typically malignant because it can erode the bone and surrounding structures, such as the pterygopalatine fossa, paranasal sinuses, and nasal cavity. It is a highly vascular tumour, sometimes from multiple Feeding arteries, and tends to bleed easily.

**CASE PRESENTATION:** In these cases, series, we reported four cases of nasopharyngeal angiofibroma in children and one case in an elderly patient. The diagnosis was made by history taking, physical examination and Cerebral MSCT Angiography, as well as Digital Subtraction Angiography (DSA). After identification of the Feeding artery, we performed transarterial embolisation using polyvinyl alcohol (PVA) foam particles.

**CONCLUSION:** Preoperative embolisation in the highly vascular tumour, such as nasopharyngeal angiofibroma, is very useful to reduce peri-operative complication of surgery. This procedure can reduce blood loss during resection of the tumour and gives better outcomes.

### Introduction

Nasopharyngeal Angiofibroma (NA) is a rare, benign and highly vascular tumour originating in the sphenopalatine foramen, and may extend to the pterygopalatine fossa, paranasal sinuses and nasal cavity [1]. They accounted for 0.05% of all head and neck tumours and reported to be 1 per 5,000-60,000 Ear Nose Throat (ENT) patients in the United States. NA occurs exclusively in men. NA generally occurs in the second decade of life between 7-19 years old and rarely occurs at the age of more than 25 years. Randowski et al., classified Nasopharyngeal Angiofibroma into three stages, based on the

expansion of the tumour (Table1) [2], [3], [4].

**Table 1: Staging systems in juvenile nasopharyngeal angiofibromas based on Randowski et al. [5]**

Stage	Description of stage
IA	Limited to the nasal cavity and / or nasopharyngeal area
IB	Same as stage I with expansion to one or more paranasal sinuses
IIA	Minimal expansion to the sphenopalatine foramen includes a minimal portion of the medial part of the pterygopalatine fossa
IIB	The tumour occupies the entire sphenopalatine fossa space, forces the posterior wall of the maxilla forward, shifts laterally or anteriorly from the maxillary artery branch, superior expansion may be present, orbital bone erosion
IIIC	Extension to the pterygopalatine fissure towards the cheek and infratemporal fossa or towards the posterior pterygoid plate
III	Erosion of the skull base (cranial base) with minimal expansion towards the intracranial
IIIB	Erosion of the skull base (cranial base) with extensive expansion in the intracranial direction with or without involving the cavernous sinus

In this article, we reported our first five

institutional cases of nasopharyngeal angiofibroma referred from the ENT department, which is four cases in children and a rare case in an elderly patient. The diagnoses were made by history taking, physical examination and radiological imaging with Cerebral and carotid Multiple Slice Computed Tomography (MSCT) angiography. All patients underwent pre-operative Digital Subtraction Angiography (DSA) to determine the arterial Feeding of the tumour, followed by endovascular embolisation using polyvinyl alcohol (PVA) foam particles. Clinical manifestations including the symptoms and signs of each case will be discussed individually, along with the description of pre and post-procedural outcome.

## Case Series

### Case 1

A 13-year-old boy presented with nasal obstruction and breathing difficulties experienced for 1 year earlier, occurring slowly and then worsening in the last 3 months. He also had epistaxis in his right nasal cavity and felt pain in his right ear. Physical examination revealed a lump in the right nasal cavity. Physical examination revealed a lump in the right nasal cavity. The result of laboratory tests, Hemoglobin (Hb) at admission was 10.5 g/dl, and postoperative Hb was 10.3 g/dl. MSCT Angiography of cerebral and carotid showed an isodense mass (30.47 HU) with intense contrast uptake. The mass was well-defined, with irregular edges covering the nasopharynx particularly at the right sphenopalatine foramen extending to the right nasal cavity, right maxillary sinus, sphenoid sinus bilateral and right ethmoidal, caused bowing of right maxillary and ethmoidal bones. It also pushed the nasal septum to the left. This patient was diagnosed with stage II right nasopharyngeal angiofibroma.

Cerebral DSA procedure was performed, and the catheter tip was navigated to the right common carotid artery (RCCA). RCCA injection revealed the feeding artery, which was originated from the C4 segment of the right internal carotid artery (RICA) and the right internal maxillary artery, a branch of the right external carotid artery (RECA). Tumour embolisation was carried out using 300-500 microns polyvinyl alcohol (PVA) foam particles, at the right internal maxillary artery, until the tumour blush decreased. Feeding artery originating from the right internal carotid artery could not be embolized for they were small and could not be reached by the available microcatheter. The post-surgical diagnosis was nasopharyngeal angiofibroma. The amount of blood loss during surgery was  $\pm$  500 cc. The patient was discharged without complication on day 6 after the operation.

30

### Case 2

A 16-year-old boy presented with left nasal obstruction in the past 4 months before admission, accompanied by epistaxis. His physical examination revealed a tumour, covering his left nasal cavity. The result of laboratory tests was as followed: Hb at admission was 11.8 g/dl, and Hb post-surgery was 7.8 g/dl. The result of MSCT Angiography of cerebral and carotid showed a centrifuging mass in the sphenopalatine canal area with a crowded vascular pattern that expanded and widened into the left maxillary sinus. The mass encroached the pterygomaxillary fossa and filled up most of the sphenoidal space area. It extended into sphenoid and ethmoid sinuses as well as to the left side of the nasal cavity which narrowed the airway. No intracranial lesions were seen. The main Feeding artery was from the branch of the left internal maxillary artery. He was diagnosed with Juvenile Nasopharyngeal Angiofibroma (JNA) with Feeding artery from an internal maxillary artery (Radkowsky Grade IIc) (Table 1).

Cerebral DSA procedure through the left external carotid artery (LECA) injection showed a tumour blush that supplied by the left internal maxillary artery. Tumour embolisation was carried out using PVA foam particles 300-500 microns in the left internal maxillary artery until the tumour blush on the left side disappeared. Tumour resection was performed afterwards. The histopathological result showed proliferation of blood vessels containing erythrocytes, between connective tissue. This finding was well-matched with angiofibroma (Figure 1). The patient was discharged 6 days after surgery without severe complications.

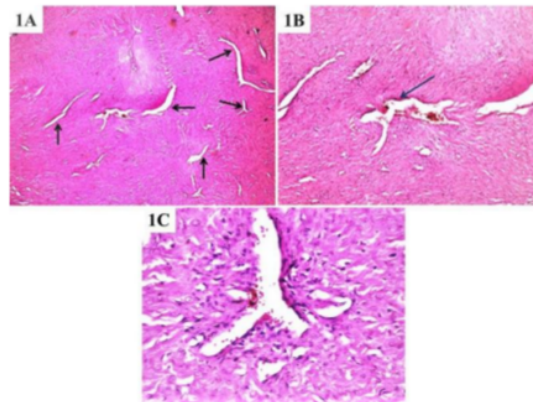


Figure 1: Histological features of angiofibroma. A) Visible erythrocyte between the proliferation of connective tissue (black arrow) 4 X magnification; B) Thin-walled vascular structure containing erythrocytes with a large layer of endothelium and fibrous component (blue arrow) 10 X magnification; C) Proliferation of connective tissue with components of fibroblast cells, with the thin layer of endothelium, 40 X enlargement (staining of hematoxylin-eosin)

41

**Case 3**

A 16-year-old boy presented with epistaxis for 4 months before admission. The epistaxis gradually worsened during the last 2 months before admission. The complaint was accompanied by nasal congestion and headache. Physical examination revealed a tumor in the right nasal cavity. The result of Hb tests was 11.2 g/dl and 10.5 g/dl for preoperative and postoperative, respectively. The result of MSCT angiography of cerebral and carotid showed a heterogeneous mass that enhances avidly upon contrast administration (90 HU). The mass showed well-definite boundaries and regular edges which originated from the right side of the nasopharynx and compressed the airway. It did not destroy the surrounding bones nor infiltrate the intracranial tissues. The Feeding artery was the right internal maxillary artery. The nasopharyngeal mass was consistent with angiofibroma. Cerebral DSA procedure was performed, and injection through RECA showed tumour blush which was supplied by the right internal maxillary artery. The tumour embolized using PVA particles 300-500 microns in the right internal maxillary artery until the tumour blush on the right side disappeared. Subsequently, resection surgery was performed with a total of  $\pm$  500 cc blood loss during the procedure. The tissue was sent to the histopathological laboratory, and the result was consistent with angiofibroma. The patient was treated for 5 days postoperatively and eventually got discharged.

**Case 4**

An 11-year-old boy visited the ENT outpatient clinic with his parents. The boy came with right nasal obstruction for 3 months before admission. Physical examination showed proptosis of the right eye and a tumour in the right nasal cavity (Figure 2). Laboratory examination showed Hb results were 14.4 gr/dl and 14.5 g/dl for preoperative and postoperative, respectively.

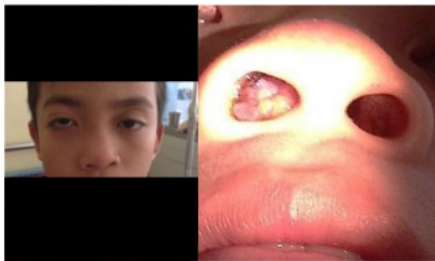


Figure 2: A) Proptosis of the right eye; B) Tumor is visible through right cavum nasi

Noncontrast CT scan on paranasal sinuses showed expansive mass with heterogeneous density, well-defined boundary, and irregular edge. The size of the mass was 4.86 x 4.34 x 4.84 cm and tended to

originate from right maxillary sinus. The tumour infiltrated the right nasal cavity, sphenoid sinus, ethmoid sinus, right frontal sinus, pressed the nasal septum to the left and caused destruction of the lateral wall of the right maxillary sinus. The diagnosis was right sinonasal mass involving more than one paranasal sinuses (Figure 3).

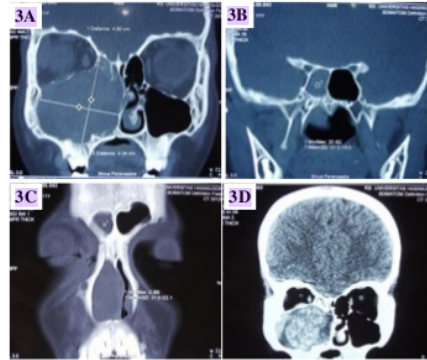


Figure 3: Paranasal Sinus CT Scan without contrast with coronal section. A) Tumours in from the right maxillary sinus compressed the right ethmoidal sinus and pushed nasal septum to the left. The tumour also destroyed the lateral wall of the right maxillary sinus; B) The tumour infiltrated the right sphenoid sinus; C) The tumour also infiltrated the right frontal sinus; D) Head CT coronal section without contrast, the nasal septum was pushed to the left, and the tumour infiltrated the ethmoidal sinus and right sphenoid sinus

Cerebral and carotid MSCT angiography revealed an isodense mass, with a regular edge, about 4.9 x 4.0 x 3.2 cm, originated from the right maxillary sinus. The tumour extended into the right nasal cavity, right ethmoidal sinus, right sphenoidal and right orbital cavity, destroyed the right maxillary and right zygomaticus bone. The right lamina papyracea of the ethmoidal bone and the nasal bone slightly pressed anteriorly (Figure 4).

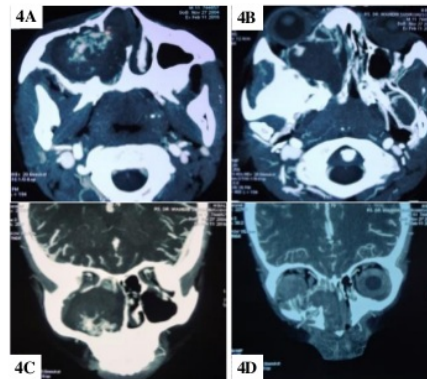


Figure 4: Cerebral and carotid MSCTA. A) There was an isodense mass with well-defined and regular edges; the size about 4.9 x 4.0 x 3.2 cm, the tumour appeared to originate from the right maxillary sinus, pressing the nasal septum to the left; B) The tumor pressed the right ethmoidal and sphenoid sinus; C) The tumour destroyed the lateral wall of right maxillary sinus and pushed nasal septum to the left; D) The tumor pressed right frontal sinus

14

The Feeding artery appeared to originate from the right internal maxillary artery (Figure 5). The diagnosis was a sinonasal mass corresponding to sinonasal angiofibroma. Cerebral DSA procedure via CA showed the presence of a tumour blush that was supplied by the right internal maxillary artery (Figure 6, A and B).

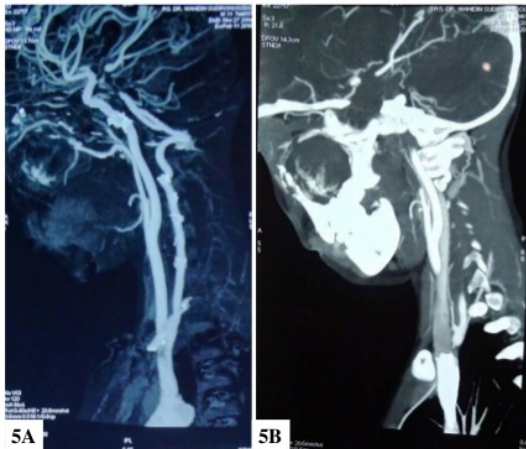


Figure 5: 3D-CTA Cerebral and carotid. A) Feeding artery was originating from the right internal maxillary artery; B) There is an isodense mass with well-defined regular edges; the size is 4.9 x 4.0 x 3.2 cm, the mass was from the maxillary sinus

Tumour embolisation was performed using PVA particles 300-500 microns through the right internal maxillary artery until the tumour blush on the right side disappeared (Figure 6, C). After that, a nasopharyngeal angiofibroma resection surgery was performed with a total of  $\pm$  500 cc of blood loss during surgery. The tissue was sent to the histopathological anatomy laboratory with the results was following angiofibroma. The patient was treated for 5 days without complications and got discharged.

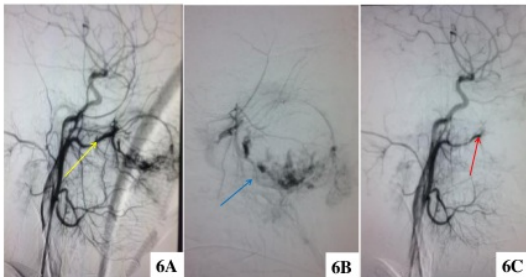


Figure 6: Digital Subtraction Angiography (DSA) cerebral, injection of the right external carotid artery (RECA). A) embolization: There was a tumour blush with Feeding artery from the right internal maxillary artery (yellow arrow); B) Tumor blush was shown by blue arrow; C) Post embolization using PVA particle, in the right internal maxillary artery until the tumour blush on the right side was no longer visible (red arrow).

## Case 5

A 61-years-old man came to the emergency department with unprovoked epistaxis for 5 months before admission. Laboratory examination showed the Hb results were 11.1 gr/dl and 10.5 g/dl for preoperative and postoperative, respectively. The results of Noncontrast CT scan on paranasal sinuses coronal view showed isodense mass (26 HU), with relatively firm boundaries, irregular edges, without calcification. The tumour was from the right nasal cavity, eroded the right maxillary, extended to the right ethmoid sinus and pressed the nasal septum contralateral. This finding was suggestive of right nasal cavity mass which extended into the right maxillary sinus and the right ethmoid sinuses. Cerebral and carotid MSCT angiography showed a mass in the right nasal cavity, which was hypervascular and originated from the right maxillary artery. Cerebral DSA procedure was performed through the right internal carotid artery (RICA). Tumour blush was seen, originated from the right ophthalmic artery (Figure 7, A and B). Injection of the RECA also showed the feeding artery from the right internal maxillary artery (Figure 7, A and B). The tumour was embolized using PVA particles 300-500 microns until the tumour blush decreased (Figure 7, C and D). The feeding artery originated from the right ophthalmic artery was not embolized because of the risk of causing blindness.

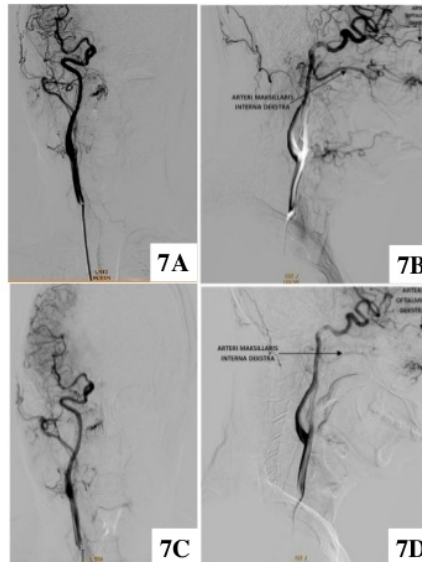


Figure 7: Digital Subtraction Angiography (DSA) Cerebral. A) Right Common Carotid Artery (RCCA) Anterior-Posterior (AP) view pre embolization. Tumour blush was seen (yellow arrow); B) Pre-embolized lateral view. The Feeding arteries were from the right internal maxillary artery and the right ophthalmic artery; C) RCCA AP view post embolization, tumour blush was still visible (black arrow); D) RCCA lateral view, post embolization, blood supply from the right internal maxillary artery did not appear, while Feeding artery from the right ophthalmic artery was still visible.

The tumour blush was still visible but decreased to some extent (Figure 7D). After that, a nasopharyngeal angiofibroma resection surgery was performed with a total of ± 500 cc blood loss intraoperative. The tissue was sent to the histopathological test, and the result was angiofibroma. The patient was treated for 5 days without complications before finally discharged.

**Pre-operative Endovascular Embolization and the Outcomes**

All patients in this case series were treated with pre-operative embolisation before tumour resection. Tumour embolisation was performed using the endovascular trans-arterial technique, with PVA foam particles (William Cook Europe ApS, Denmark) as embolic material. The procedure was coded as Percutaneous Transcatheter Infusion Embolization (ICD-9-CM 99.29).

Cerebral DSA procedures were performed in case 1 and 4 with asepsis preparation and general anaesthesia. The right femoral artery was catheterised, using a 6F sheath (Merit Medical Systems Inc., South Jordan, Utah, USA), and a 6F JR4 guide catheter (Terumo Corporation, Tokyo, Japan). The procedure was followed by tumour embolisation, using a 6F JR4 guide catheter (Terumo Corporation, Tokyo, Japan), 2.4F microcatheter (Terumo Corporation, Tokyo, Japan) and 1.4 micro guidewires (Terumo Corporation, Tokyo, Japan).

Cerebral DSA procedure was performed in case 2 with asepsis preparation and local anaesthesia. The right femoral artery was catheterised using 6F sheath (Merit Medical Systems Inc., South Jordan, Utah, USA), 5F HH1 guide catheter (Terumo Corporation, Tokyo, Japan), 6F JR3.5 catheter (Terumo Corporation, Tokyo, Japan). Subsequent tumour embolisation was done by using a 6F JR3.5 guide catheter (Terumo Corporation, Tokyo, Japan), 2.4F microcatheter (Terumo Corporation, Tokyo, Japan) and 1.4F micro guidewire (Terumo Corporation, Tokyo, Japan) and particulate PVA contour 300-500 microns.

Cerebral DSA procedure in case 3 was performed with asepsis preparation and local anaesthesia, right femoral artery catheterised with 6F sheath (Merit Medical Systems Inc., South Jordan, Utah, USA), and 6F JR4 guide catheter (Terumo Corporation, Tokyo, Japan).

Cerebral DSA procedure in case 5 was performed with asepsis preparation and local anaesthesia, right femoral artery was catheterized using 6F sheath (Merit Medical Systems Inc., South Jordan, Utah, USA), 6F JR4 guide catheter (Terumo Corporation, Tokyo, Japan), and 0.038 guidewire (Terumo Corporation, Tokyo, Japan). The procedure was followed by tumour embolisation procedure; using 6F JR4 guide catheter (Merit Medical Systems Inc.,

South Jordan, Utah, USA), 1.8F microcatheter (Terumo Corporation, Tokyo, Japan) 1.4F micro guidewire (Terumo Corporation, Tokyo, Japan) and particulate PVA contour 300-500 microns.

The result of tumour embolisation in case 2, 3 and 4 was satisfactory, with the total disappearance of tumour blush. In case 1 and case 5, the tumour blush is still visible, although reduced to some extent, because the tumour was also received blood supply from the right internal carotid artery case 1, and the right ophthalmic artery case 5 (Table 2). Within 2 to 3 days of embolisation, the patients underwent tumour resection surgery and postoperative treatment for approximately 5-6 days. All the patients were discharged with good outcome and without any complications.

**Table 2: Demographic, laboratory, and radiological characteristic of each patient**

Cases	Sex	Age /yrs	Pre-Op. Hb (g/dl)	Post-Op. Hb (g/dl)	MSCT Scan of Cerebral and Carotid Angiography (Arterial Feeding)	DSA Arterial Feeding
1	M	13	10.5	10.3	Right internal maxillary artery, a branch of the external carotid artery	C4 segment of the right internal carotid artery; Right Internal maxillary artery, a branch of the external carotid artery
2	M	11	11.8	7.8	Left internal maxillary artery, a branch of the external carotid artery	Left internal maxillary artery, a branch of the external carotid artery
3	M	16	11.2	10.5	Right internal maxillary artery, a branch of the external carotid artery	Right internal maxillary artery, a branch of the external carotid artery
4	M	11	14.4	14.5	Right internal maxillary artery, a branch of the external carotid artery	Right internal maxillary artery, a branch of the external carotid artery
5	M	61	11.1	10.5	Right internal maxillary artery, a branch of the external carotid artery	Right internal maxillary artery, a branch of the external carotid artery and Right ophthalmic artery

**Discussion**

Nasopharyngeal angiofibroma (NA) was first described in ancient times by Hippocrates (5<sup>th</sup> century BC). NA is a rare benign fibrovascular tumour, at the superoposterior area of the sphenopalatine foramen and is often found in young men, between 14-25 years old. It is estimated to be 0.05% of all benign Head and Neck tumours. These tumours are histologically benign, yet clinically destructive. The most common presenting symptoms are unilateral nasal congestion, nasopharyngeal lump and recurrent epistaxis. In the later stages, this tumour can cause facial deformity, proptosis, headache and deafness. Computed tomography (CT-Scan) and magnetic resonance imaging (MRI) is the most widely used modalities for diagnosis and evaluation of tumour growth, bone destruction and staging of angiofibroma. Also, a pre-operative angiographic procedure is performed to identify Feeding artery and to describe tumour size and location [1], [6], [7]. In our case series, 4 patients were aged between 14-25 and

1 patient was 61 years old, thus considered as a rare case. All patients are male. Almost all patients presented with the chief complaint of nasal congestion, difficulty breathing, epistaxis as well as mass in the nasal cavity. The diagnosis was confirmed by radiological examination in the form of cerebral and carotid MSCT angiography and digital subtraction angiography (DSA).

Surgical resection of nasopharyngeal angiofibroma is the mainstay of treatment. Other treatment modalities include radiation, cryotherapy, electrocoagulation, hormonal therapy, embolisation and injection of sclerosing agents [8],[9]. Although surgical excision is the definite treatment, the risk of this procedure is high, particularly due to the high risk of bleeding, since the tumour is highly vascularized. Fonseca et al. reported that there was no significant difference in bleeding risk between 15 patients who undergo surgery without preoperative embolisation and those with pre-operative embolisation [10]. Gaillard et al. reported that there could be the risk of tumour recurrence in patients who were not pre-operatively embolized. Furthermore, Gaillard confirmed that cure rates could be as high as 94% if pre-operative tumour embolisation is performed [11].

In our institution, this is the first serial cases of preoperative tumour embolisation for nasopharyngeal angiofibroma, before tumour resection was performed. Embolisation is a minimally invasive procedure, aimed at devascularization of tumour or cerebrovascular malformation. A catheter is passed through femoral, navigated until its tip is in the target vessel. In this case, the target vessel is the Feeding artery of the nasopharyngeal tumour. An embolisation agent is then ejected through the catheter tip into the blood vessel to revascularize the tumour.

In all five cases, the internal maxillary artery, a branch of the external carotid artery, is the main Feeding artery for the Nasopharyngeal Angiofibroma (Table 21) but there are other Feeding arteries, such as the C4 segment of the right internal carotid artery and the right ophthalmic artery. After the Feeding artery was identified, pre-operative tumour embolisation was performed using the PVA foam particle agent. PVA foam particle is routinely used as embolisation agent for preoperative embolisation. PVA can produce permanent and non-absorbing occlusion, with a low rate of blood vessel recanalisation. All five patients experienced anaemia both before and after tumour embolisation and tumour resection. All patients underwent tumour resection after the pre-operative embolisation. During the surgical procedure, the blood loss is only around 500 cc, and all patients were discharged, after 5-6 days of postoperative treatment, without any severe complications.

In conclusion, preoperative embolisation of the Feeding artery for Nasopharyngeal Angiofibroma is a very advisable procedure. Pre-operative

embolisation can reduce blood loss during peri-operative surgical operation and improve outcome. In our institution, we routinely perform it. Before embolisation procedure, thorough evaluation with MSCT angiography and DSA must be performed to evaluate the Feeding artery.

## Acknowledgements

The authors wish to acknowledge the invaluable assistance given to them by the nursing and all members of Brain Centre, Dr Wahidin Sudirohusodo General Hospital, and Hasanuddin University Teaching Hospital, Makassar, South Sulawesi, Indonesia in the management of the patients and the preparation of this paper for publication.

## References

1. Ahmed Ashrafi SK, Suhail Z, Khambaty Y. Postembolization infarction in juvenile nasopharyngeal angiofibroma. *J. Coll Physicians Surg Pak.* 2011; 21(2):115-6.
2. Antoniadis K, Antoniadis DZ, Antoniadis V. Juvenile angiofibroma: Report of a case with intraoral presentation. *Oral Surg Oral Med Oral Pathol Oral Radiol Endod.* 2002; 94(2):228-32. <https://doi.org/10.1067/moe.2002.125582> PMID:12221391
3. Garca MF, Yuca SA, Yuca K. Juvenile Nasopharyngeal Angiofibroma. *Eur J Gen Med.* 2010; 7 (4):419-25. <https://doi.org/10.29333/ejgm/82897>
4. Baptista MAFB, Pinna FR, Voegels RL. Extra nasopharyngeal angiofibroma originating in the inferior turbinate: a distinct clinical entity at an unusual site. *Int Arch Otorhinolaryngol.* 2014; 18:403-405. <https://doi.org/10.1055/s-0034-1387811> PMID:25992131 PMID:PMC4297003
5. Radkowski D, McGill T, Healy GB, Ohlms L, Jones DT. Angiofibroma. Changes in staging and treatment. *Arch Otolaryngol Head Neck Surg.* 1996; 122(2):122-9. <https://doi.org/10.1001/archotol.1996.01890140012004> PMID:8630204
6. Rahma S, Et al. Nasopharyngeal Angiofibroma in Adults. Department of Ear Nose Throat Head Neck Surgery. Faculty of Medicine, Andalas University, Padang.
7. Anggreani L, Et al. Description of Estrogen  $\beta$  Receptor Expression on Young Nasopharyngeal Angiofibromas Using Immunohistochemical Examination. Department of Ear Nose Throat Head Neck Surgery. Faculty of Medicine, University of Indonesia Jakarta.
8. Maniglia AJ, Mazzarella LA, Minkowitz S, et al. Maxillary sinus angiofibroma treated with cryosurgery. *Arch Otolaryngol.* 1969; 89:111-116. <https://doi.org/10.1001/archotol.1969.00770020529015> PMID:4303494
9. Chen WL, Huang Z, Li J, Chai Q, Zhang D. Percutaneous sclerotherapy of juvenile nasopharyngeal angiofibroma using fibrin glue combined with OK-432 and bleomycin. *International journal of Pediatric Otorhinolaryngology.* 2010; 74:422-5. <https://doi.org/10.1016/j.ijporl.2010.02.002> PMID:20189660
10. Fonseca AS, Vinhaes E, Boaventura V, et al. Surgical treatment of non-embolized patients with nasopharyngeal angiofibroma. *Braz J Otorhinolaryngol.* 2008; 74:583-587. [https://doi.org/10.1016/S1808-8694\(15\)30607-8](https://doi.org/10.1016/S1808-8694(15)30607-8)
11. Gaillard AL, Anastácio VM, Piatto VB, Maniglia JV, Molina FD. A seven-year experience with patients with juvenile nasopharyngeal angiofibroma. *Braz J Otorhinolaryngol.* 2010; 76(2):245-250. <https://doi.org/10.1590/S1808-8694201000200016> PMID:20549087

# Case Series of Pre-Operative Endovascular Embolization of Nasopharyngeal Angiofibroma Using Polyvinyl Alcohol Foam Particle: A Single Centre Experience

## ORIGINALITY REPORT

% **18**  
SIMILARITY INDEX

% **7**  
INTERNET SOURCES

% **15**  
PUBLICATIONS

% **4**  
STUDENT PAPERS

## PRIMARY SOURCES

- 1** "Juvenile Angiofibroma", Springer Nature, 2017  
Publication % **1**
- 2** "All Around the Nose", Springer Science and Business Media LLC, 2020  
Publication % **1**
- 3** René Djindjian, Jean-Jacques Merland. "Super-Selective Arteriography of the External Carotid Artery", Springer Nature, 1978  
Publication % **1**
- 4** [epdf.tips](#)  
Internet Source % **1**
- 5** Chen, Mu-Kuan, Yao-Lung Tsai, Kua-Wai Lee, and Cheng-Chuan Chang. "Strictly endoscopic and harmonic scalpel-assisted surgery of nasopharyngeal angiofibromas: eligible for advanced stage tumors", Acta Oto-Laryngologica, 2006.  
Publication % **1**

6

Eirin Esaiassen, Erik Hjerde, Jorunn Pauline Cavanagh, Gunnar Skov Simonsen, Claus Klingenberg. "Bifidobacterium Bacteremia: Clinical Characteristics and a Genomic Approach To Assess Pathogenicity", Journal of Clinical Microbiology, 2017

Publication

% 1

7

Encyclopedia of Otolaryngology Head and Neck Surgery, 2013.

Publication

% 1

8

Geert Maleux, Diethard Monbaliu, Chris Verslype, Christophe Casteleyn et al. "Percutaneous isolated liver perfusion with occlusion balloons and a catheter-based stent-graft-like perfusion device: an experimental study in a porcine model", European Radiology, 2010

Publication

% 1

9

[www.campbellsci.com.br](http://www.campbellsci.com.br)

Internet Source

% 1

10

Robert Thayer Sataloff. "Computed tomography of the face and paranasal sinuses: Part II. Abnormal anatomy and pathologic conditions", Head & Neck Surgery, 05/1985

Publication

% 1

11

David L Hicks. "Nasal Solitary Fibrous Tumor Arising from the Anterior Cranial Fossa", Skull

<% 1

# Base Surgery, 11/2004

Publication

12

[www.ijcmsr.com](http://www.ijcmsr.com)

Internet Source

<% 1

13

[www.thieme-connect.de](http://www.thieme-connect.de)

Internet Source

<% 1

14

[pesquisa.bvsalud.org](http://pesquisa.bvsalud.org)

Internet Source

<% 1

15

Fernando V. Viñuela. "Detachable calibrated-leak balloon for superselective angiography and embolization of dural arteriovenous malformations", *Journal of Neurosurgery*, 06/1983

Publication

<% 1

16

Suvi Renkonen, Valtteri Häyry, Päivi Heikkilä, Ilmo Leivo, Caj Haglund, Antti A. Mäkitie, Jaana Hagström. "Stem cell-related proteins C-KIT, C-MYC and BMI-1 in juvenile nasopharyngeal angiofibroma—do they have a role?", *Virchows Archiv*, 2010

Publication

<% 1

17

Submitted to University of Sheffield

Student Paper

<% 1

18

Donald, Paul J.. "♦ Treatment", *The Difficult Case in Head and Neck Cancer Surgery*, 2010.

Publication

<% 1

19

Neurointervention in the Medical Specialties, 2015.

Publication

&lt;% 1

20

Mete Iseri, Murat Ozturk, Deniz Filinte, Funda Corapcioglu. "A peripheral primitive neuroectodermal tumor arising from the middle turbinate and transnasal endoscopic approach for its surgical treatment", International Journal of Pediatric Otorhinolaryngology Extra, 2007

Publication

&lt;% 1

21

Andracchi, S.. "Visual loss from arterial steal in patients with maxillofacial arteriovenous malformation", Ophthalmology, 200004

Publication

&lt;% 1

22

[www.meditrenz.com](http://www.meditrenz.com)

Internet Source

&lt;% 1

23

Szyma ska, A., M. Szyma ski, E. Czekajska-Chehab, and M. Szczerbo-Trojanowska. "Invasive growth patterns of juvenile nasopharyngeal angiofibroma: radiological imaging and clinical implications", Acta Radiologica, 2014.

Publication

&lt;% 1

24

Bashar Abuzayed, Bulent Canbaz, Galip Zihni Sanus, Seckin Aydin, Harun Cansiz. "Combined craniofacial resection of anterior skull base tumors: long-term results and experience of

&lt;% 1

---

25 Submitted to University of Nottingham <% 1  
Student Paper

---

26 www.jpma.org.pk <% 1  
Internet Source

---

27 A. R. Talbot. "Paraganglioma of the maxillary  
sinus", The Journal of Laryngology & Otology,  
03/1990 <% 1  
Publication

---

28 europepmc.org <% 1  
Internet Source

---

29 D. D. Vele, S. K. Sengupta, S. P. Dubey, M. K.  
Dokup. "Cystic lesions of the nasal cavity and  
the paranasal sinuses: report of two unusual  
cases", The Journal of Laryngology & Otology,  
2007 <% 1  
Publication

---

30 P. Ryan Camilon, Reza Rahbar, Michael J.  
Cunningham, Eelam A. Adil. "Juvenile  
nasopharyngeal angiofibroma in prepubertal  
males: A diagnostic dilemma", The  
Laryngoscope, 2019 <% 1  
Publication

---

31 www.bjorl.org <% 1  
Internet Source

---

32

Soheila Maleki. "Structural, chemical and immunogenic effects of roasting peanut", World Allergy Organization Journal, 11/2007

Publication

<% 1

33

[www.thieme-connect.com](http://www.thieme-connect.com)

Internet Source

<% 1

34

[www.bjorl.org.br](http://www.bjorl.org.br)

Internet Source

<% 1

35

[www.scielo.br](http://www.scielo.br)

Internet Source

<% 1

36

Hiroto Miwa. "Rikkunshito, a traditional Japanese medicine, may relieve abdominal symptoms in rats with experimental esophagitis by improving the barrier function of epithelial cells in esophageal mucosa", Journal of Gastroenterology, 12/18/2009

Publication

<% 1

37

"Catheter-Based Cardiovascular Interventions", Springer Nature, 2013

Publication

<% 1

38

Zebin Xiao, Yingyan Zheng, Jian Li, Dehua Chen, Fang Liu, Dairong Cao. "Four-dimensional CT angiography (4D-CTA) in the evaluation of juvenile nasopharyngeal angiofibromas: comparison with digital subtraction angiography (DSA) and surgical

<% 1

39

[www.rcsed.ac.uk](http://www.rcsed.ac.uk)

Internet Source

<% 1

---

40

L. Pupp, L. Huszár. "Angioma of the internal maxillary artery producing massive recurrent epistaxis", The Journal of Laryngology & Otology, 2007

Publication

<% 1

---

41

Micro-endoscopic Surgery of the Paranasal Sinuses and the Skull Base, 2000.

Publication

<% 1

---

42

H. Glad, B. Vainer, C. Buchwald, B.L. Petersen, S.A. Theilgaard, P. Bonvin, C. Lajer, J. Jakobsen. "Juvenile nasopharyngeal angiofibromas in Denmark 1981–2003: diagnosis, incidence, and treatment", Acta Oto-Laryngologica, 2009

Publication

<% 1

---

43

Shufeng Yi, Fan Yang, Cunle Jie, Guiqin Zhang. "A novel strategy to the formulation of carmustine and bioactive nanoparticles co-loaded PLGA biocomposite spheres for targeting drug delivery to glioma treatment and nursing care", Artificial Cells, Nanomedicine, and Biotechnology, 2019

Publication

<% 1

---

44

Submitted to Bridgepoint Education

Student Paper

&lt;% 1

45

Ketil Natvig, Ingar O. Skalpe. "Pre-operative embolization of Juvenile nasopharyngeal angiofibromas with gelfoam", The Journal of Laryngology & Otology, 2007

Publication

&lt;% 1

46

Wormald, Peter-John. "Endoscopic Resection of Tumors Involving the Maxillary Sinus, Pterygopalatine Fossa, and Infratemporal Fossa", Endoscopic Sinus Surgery, 2013.

Publication

&lt;% 1

47

T. Terada, N. Miyatake, D. Naka, M. Tsuura, H. Matsumoto, O. Masuo, T. Itakura. "Indirect Carotid Cavernous Fistula Appeared after Balloon Embolization of Direct CCF", Acta Neurochirurgica, 2002

Publication

&lt;% 1

48

Lisa A. Brown, Stephanie A. Joe. "Inferior Turbinate Angiofibroma in a Middle-Aged Man", Ear, Nose & Throat Journal, 2019

Publication

&lt;% 1

49

Muhammed, NA, I Mohamad, and B Abdullah. "Antrochoanal polyp mimicking juvenile nasoangiofibroma", Bangladesh Journal of Medical Science, 2013.

Publication

&lt;% 1

---

EXCLUDE QUOTES ON

EXCLUDE  
BIBLIOGRAPHY ON

EXCLUDE MATCHES < 5  
WORDS